

Equine Stromal Corneal Ulcers FAQs

UTCVM OPHTHALMOLOGY

What is a corneal ulcer?

A corneal ulcer, sometimes called a corneal scratch, is caused by the loss of a portion of the cornea. This may be just the top layer (epithelium) which is referred to as a superficial corneal ulcer or deeper into the second layer (stroma) which is referred to as a deep or stromal corneal ulcer.

How is a corneal ulcer diagnosed?

A special dye called fluorescein stain highlights the loss of epithelium. Positive dye uptake on the cornea indicates a corneal ulcer is present. Horses with a corneal ulcer are most often uncomfortable and show signs of squinting (holding the eyelids closed), excessive tearing, and cloudiness to the eye.

How long should it take for the corneal ulcer to heal?

In the case of a simple, superficial corneal ulcer, the ulcer should heal within 7 days, and sometimes will heal sooner. If the ulcer is not healed in 7 days it is considered complicated, indicating there is an underlying condition preventing it from healing (e.g., plant material rubbing on the cornea), the ulcer is indolent (special type of superficial ulcer), or most commonly in horses a secondary infection has occurred.

What is an infected corneal ulcer?

A corneal ulcer can become secondarily infected with bacteria or fungus from the environment. Bacteria and/or fungus produce degrading enzymes that break down and “eat” the corneal structure. This can occur quickly in many cases (over several hours or days) and results in the loss of the cornea leading to a deep ulcer and/or softening of the tissue leading to “melting”. When the cornea is infected, the inside of the eye responds by becoming very inflamed, called uveitis. The inflammation is directly correlated to the severity of the infection.

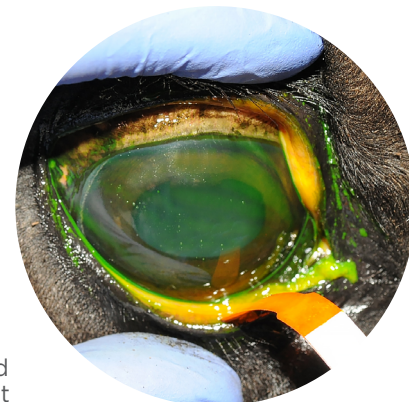
How are infected corneal ulcers treated differently?

The treatment of infected or stromal ulcers depends on the cause and depth. **Intensive** antimicrobial and serum treatment is prescribed following diagnosis of an infected corneal ulcer (often every 1-2 hours at first). The frequency of treatment is only reduced after the infection is stabilized. Other prescribed medications can include pain medications and anti-inflammatories. If prescribed, always leave the protective eye mask (EyeSaver™ or Equivizor™) in place to prevent self-trauma; especially because deep ulcers are at risk of rupture if self-traumatized. Medical treatment can take anywhere from 3-12 weeks to heal completely.

When is surgery indicated?

Grafting surgery is often recommended for stromal ulcers greater than 70% depth, descemetocoeles, ulcers that are rapidly progressing despite treatment, or ulcers that are “melting”. The goal of surgery is to stabilize the ulcer, prevent rupture of the eye, and save vision. Surgery can shorten the time frame of treatment and give a more predictable outcome in some cases. However, some ulcers are so large that grafting surgery could blind the eye and this needs to be taken into consideration before deciding if this surgery is right for your horse. Additionally, severe corneal

Fluorescein stain is applied to the surface of the eye to evaluate for breaks in the corneal epithelium. Positive stain uptake indicates a corneal ulcer.



ulcers or ruptures that fail to heal may be best treated with removal of the affected eye (enucleation) for patient comfort.

How do I know if my horse's eye worsens or ruptures and what do I do?

To try and prevent rupture of an eye with a deep or infected ulcer it is important to keep your horse quiet and prevent pressure on the eye. To accomplish this, we recommend the use of a protective eye mask, stall rest with hand walking only, and taking great care when applying eye medications and cleaning around the eye. The use of a subpalpebral lavage (SPL) system will be useful to prevent having to touch your horse's eye or head during medicating. Monitor for signs of rupture including blood or excess fluid running from the eye and/or sudden unwillingness to open the eye. Additional concerns indicating worsening include *increased* cloudiness, yellow/green discharge, or greater discomfort. Please call your veterinary professional if you are concerned the condition has worsened as this may warrant an emergency re-check.

What else should I look out for?

Horses that have eye pain are at increased risk of colic. Monitor for normal water intake and manure output. Please ensure your horse always has access to fresh water. Hand walking several times a day can improve gastrointestinal motility. If your horse has decreased manure output or shows signs of colic (laying down more frequently than normal, inappetence, looking at their belly, and pawing) please contact your veterinarian immediately.

Eye protection is often needed when a horse has a deep ulcer to prevent the horse from rubbing and causing more damage to the already fragile eye.

